



The Root Membrane Concept: In the Zone With the “Triangle of Bone”

*Authored by Scott D. Ganz, DMD; Isaac Tawil, DDS, MS; and
Miltiadis E. Mitsias, DDS, MSc, PhD*

Upon successful completion of this CE activity, 2 CE credit hours may be awarded.

Opinions expressed by CE authors are their own and may not reflect those of *Dentistry Today*. Mention of specific product names does not infer endorsement by *Dentistry Today*. Information contained in CE articles and courses is not a substitute for sound clinical judgment and accepted standards of care. Participants are urged to contact their state dental boards for continuing education requirements.

The Root Membrane Concept: In the Zone With the “Triangle of Bone”

Effective Date: 10/01/17 Expiration Date: 10/01/20

About the Author



Dr. Ganz graduated from the University of Medicine and Dentistry of New Jersey (UMDNJ) Dental School and then completed a 3-year specialty program in maxillofacial prosthetics at MD Anderson Cancer Center in Houston. He is a member of the board of directors of the International Congress of Oral Implantologists (ICOI), a Fellow of the Academy of Osseointegration (AO), on staff at Hackensack University Medical Center, and on faculty at Rutgers School of Dental Medicine. He was a founding member of the Siplant Academy, headquartered in Lueven, Belgium, and past president

of both the Computer Aided Implantology Academy, and the NJ section of the American College of Prosthodontists. He has served as a consultant for numerous dental companies for the past 27 years. He is on the editorial staff of several publications, published more than 100 articles in scientific journals, and has contributed to 14 textbooks to date. He also authored *An Illustrated Guide to Understanding Dental Implants* and co-authored *Computer Guided Applications for Dental Implants, Bone Grafting, and Reconstructive Surgery* (Elsevier). He continues to present worldwide on the prosthetic and surgical phases of implant dentistry, and has been a featured speaker for the AO, ICOI, American Academy of Implant Dentistry, and many others. He is considered one of the world's leading experts in the field of computer utilization for diagnostic 3-D imaging, CBCT, CAD/CAM, and treatment planning applications in dentistry. He can be reached via email at drganz@drganz.com.

Disclosure: Dr. Ganz is the co-director of Advanced Implant Education (AIE) (Brooklyn, NY), the director of the Ganz Institute of Applied 3-D Implant Reconstruction, and a lecturer for integrated dental systems.

Dr. Mitsias graduated with a dental degree from the National and Kapodistrian University of Athens (Greece) in 2000. By 2003, he completed his graduate studies at New York University (NYU) in the implant department—where, in his last year, he became a teaching fellow—while simultaneously completing a master's program in NYU's department of biomaterials and biomimetics. He has been an instructor in the department of prosthodontics at the University of Athens since 2005, as well as a research associate at the University of Kiel, Germany, where he completed his PhD. In 2010, he joined as visiting faculty at NYU in the department of periodontology and implant dentistry. He maintains a private practice in Athens, has lectured internationally, and his articles have been published in several scientific journals. He can be reached via either of these email addresses: mmitsias@msn.com or miltiadis.mitsias@nyu.edu.

Disclosure: Dr. Mitsias reports no disclosures.

Dr. Tawil received a master's degree in biology from Long Island University (Brookville, NY) and his DDS degree from the NYU College of Dentistry. He is a Diplomate of the International Academy of Dental Implantology (IADI) and the

International Academy for Dental Facial Esthetics. He is a Fellow of the ICOI and the Advanced Dental Implant Academy. Dr. Tawil maintains a private practice and is the founder and co-director of AIE, both of which are located in Brooklyn. He is a “MINEC Knight” in the MegaGen International Network of Educators and Clinicians, as well as new product consultant for the company integrated dental systems. He has been published in several magazines and journals and teaches live surgical seminar hands-on courses internationally. He can be reached at iketawil@mac.com.

Disclosure: Dr. Tawil reports no disclosures.

INTRODUCTION

Implant dentistry has continued to evolve with refined techniques for immediate or delayed loading, immediate extraction placement, bone grafting, guided surgery applications, and restorative options. However, the importance of the diagnostic process of dental implant reconstruction cannot be underestimated to achieve both functional and aesthetic outcomes. The advent of 3-D imaging modalities and interactive treatment planning software has provided clinicians with an enhanced set of tools for accurate assessment of each individual patient presentation, especially when implant reconstruction may be considered. When evaluating potential implant receptor sites, it is important to appreciate the volume of bone, the thickness of the cortical plates, bone density, bony topography, and the position of existing tooth roots within the alveolus. The difficulty continues in finding agreement as to where an implant should be placed within a potential receptor site.

The “Triangle of Bone” (TOB) concept was initially conceived in 1992 and first published in 1995 to help define a “zone” of available bone for implant placement—originally by using computed tomography (CT) scan imaging.¹ The protocol has continued to evolve within subsequent publications with the advent of cone beam CT (CBCT) and the development of various treatment planning software applications with advanced diagnostic functionality. The goal is always to place the implant in a restoratively driven position while preserving or augmenting the preexisting bone.

When teeth are still present, the relationship between the trajectory of the alveolus and the position of the root is critical when assessing for implant placement. The cross-sectional slice is one of the many views that are essential for the diagnostic phase utilizing the TOB concept (Figure 1a). The trajectory of the alveolus as it relates to the tooth root can be assessed with the existing bone volume or potential zone within the TOB for implant placement (Figure 1b). If it is desired to surround the implant with the most volume of bone, the implant is positioned to bisect the TOB (Figure 2a, cyan line), necessitating a cement-retained restorative protocol. The apical position of the implant should be directed buccally within the TOB for a

The Root Membrane Concept: *In the Zone With the “Triangle of Bone”*

screw-retained restoration (Figure 2b). Therefore, it is possible to predict aspects of the prosthetic phase using the TOB concept.

It is well known that tooth extraction alone, or when followed by immediate implant placement, can lead to crestal alveolar bone and soft-tissue loss. The buccal plate is extremely thin and can be easily compromised after tooth extraction, leading to aesthetic issues. Innovative concepts continue to evolve in an attempt to meet the demands of maintaining both the bone and the soft tissue, especially when teeth are present in the anterior maxilla. When a tooth is extracted, the resulting socket will then receive an implant, often leaving a “gap” between the implant and the buccal cortical plate of bone. Certain clinicians have recommended grafting the gap, while others do not. In either situation, the biological entity that surrounds the natural tooth—the periodontal ligament and the vascularization of the area—is compromised.

To counter the negative effects of removing the tooth root, techniques have been published that recommend leaving a portion of the root intact, helping to preserve the periodontal ligament and associated fibers. These techniques include the *Root Membrane Concept*,² *Socket-Shield*,³ and *Partial Extraction Therapy*⁴ (PET). When considering such a protocol, CBCT diagnosis is essential in helping to visualize the portion of the root that will remain as depicted in the cross-sectional or sagittal slice (Figure 3a). Once the palatal aspect of the root has been sectioned and removed, an implant can be placed, usually with the apical aspect of the implant placed palatally and, in many examples, the position is usually within the zone of the TOB. Upon closer inspection of the cross-sectional CBCT slice, there is a danger that the threads of the implant may be in contact with the root (Figure 3b). Any contact with the fragment can dislodge the root and is contraindicated. Therefore, to ensure that the root remnant is thin enough and in a proper shape to avoid the implant, the root needs to be modified.

Recently, a new kit was introduced that provides a series of drills that can be used to accurately prepare the “root membrane” to help preserve the buccal bone during implant reconstruction. Once the root has been sectioned and the palatal aspect has been removed, the remaining root membrane can be carefully contoured and beveled to leave adequate room for the osteotomy preparation (Figure 4).

CASE REPORT

A 28-year-old male presented with pain upon chewing for a duration of several weeks. His medical history was unremarkable. The maxillary second bicuspid had a history of root canal therapy, and the patient was referred to an endodontist for further diagnosis (Figure 5). A CBCT did not reveal a fracture; however, the

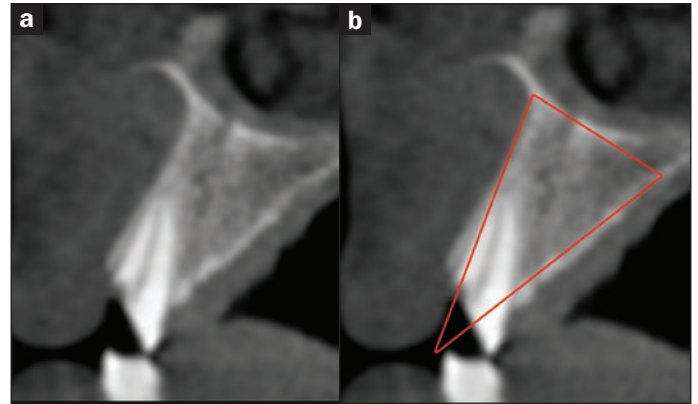


Figure 1. (a) The cross-sectional slice revealing the alveolar bone and (b) the trajectory of the tooth root within the alveolus to be assessed as a “zone” within the “Triangle of Bone” (TOB) for implant placement.

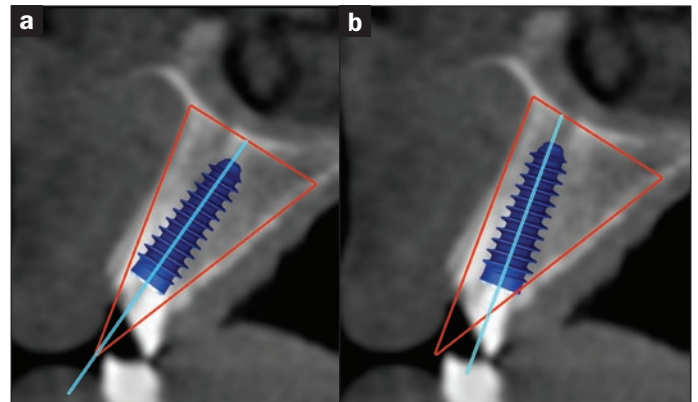


Figure 2. It is possible to predict aspects of the prosthetic phase (cyan line) using the TOB concept for (a) the cement-retained restorative protocol or (b) a screw-retained restoration in which the apical position of the implant is directed buccally.

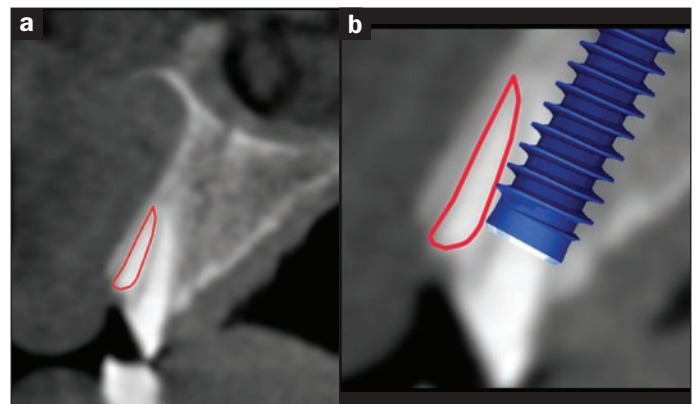


Figure 3. (a) The root fragment that will remain is depicted in the cross-sectional or sagittal slice (red outline), and (b) the enlarged image reveals the proximity of the simulated implant threads to the root.

The Root Membrane Concept: *In the Zone With the “Triangle of Bone”*

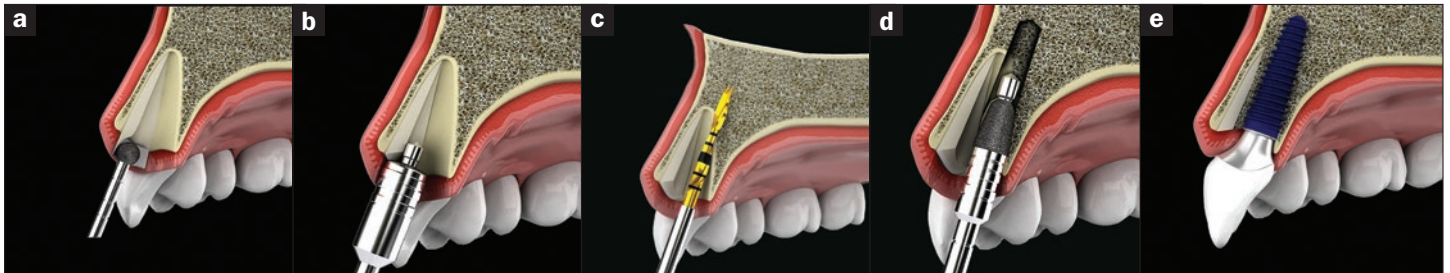


Figure 4. (a) Modification of the root membrane with a round diamond; (b) further contouring; (c) palatal position for osteotomy; (d) a cone-shaped diamond used to refine the osteotomy; and (e) the implant, positioned to avoid the root membrane.

clinical indication was that a fracture was present (Figure 6a). After a discussion with the patient, the alveolus was examined as a potential implant receptor site (Figure 6b). After further review of the root structure and the trajectory of the alveolus in the cross-sectional CBCT slices, it was determined that there was enough bone volume for an immediate extraction and implant placement. To help preserve the buccal bone, it was elected to section the tooth and maintain the root membrane. The Root Membrane Kit (RMK) (integrated dental systems) contains a step-by-step protocol to remove the gutta-percha, section the tooth, and contour the root in anticipation of the implant (Figure 7).

According to protocol, the coronal aspect of the tooth was removed, leaving access to the root. The root was then sectioned horizontally (Figure 8), and the palatal aspect was carefully removed (Figure 9). The diamond drills of the RMK helped to carefully contour the root remnant into a c-shape. The coronal aspect of the root was recontoured to provide room for the implant (Figure 10). Once the root membrane was prepared, the osteotomy could then be initiated in a palatal location within the TOB. A 4.5-mm diameter by 13.0-mm length implant (AnyRidge [integrated dental systems]) was then carefully placed, gaining apical stabilization at 45 Ncm of torque (Figure 11). Using resonance frequency analysis, an implant stability quotient (ISQ) value of 78 was recorded (Mega ISQ [integrated dental systems]). Based upon the protocol documented by Siompas et al² during the past 10 years, the residual buccal gap was not filled with bone. However, as the implant was well-fixated, it was elected to use a one-stage surgical approach using platelet-rich fibrin wrapped around a titanium healing collar in a “poncho” technique (Figure 12).

The occlusal view of the implant site is seen in Figure 13a and after suturing in Figure 13b. A periapical radiograph reveals the excellent positioning of the implant (Figure 14).

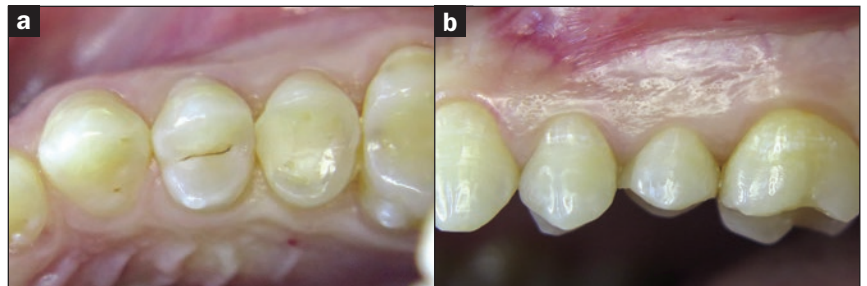


Figure 5. The maxillary second bicuspid had a history of root canal therapy, as seen in the (a) occlusal and (b) lateral retracted intraoral views.

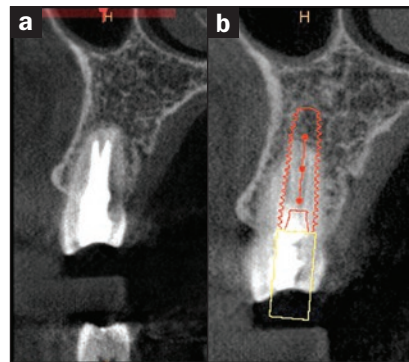


Figure 6. (a) The cross-sectional image could not confirm a root fracture, but was (b) useful to assess the remaining bone as a potential implant receptor site.

The 2-week follow-up appointment revealed the site’s excellent healing (Figure 15).

IN SUMMARY

It is well established that bone preservation is vital to long-term implant success, and that the loss of both hard and soft tissue can lead to functional and aesthetic complications. The TOB concept identifies a zone within the available bone as seen in the cross-sectional CT and CBCT images. The TOB is a useful concept when planning for implants, bone grafting, and in anticipation of the restorative components needed for cement-retained or screw-retained restorations. The concept

The Root Membrane Concept: *In the Zone With the “Triangle of Bone”*

is to maximize bone volume surrounding the potential implant within the receptor site or suggest when bone grafting may be recommended (Figure 16). It should be noted that the single cross-sectional slice could represent a slice thickness of less than 0.2 mm, and, therefore, it should be required when choosing an implant position that all other views afforded by the 3-D imaging modality and interactive treatment planning software be fully appreciated.

Through the use of CT and, now, CBCT imaging, the “Reality of Anatomy,” as described by Ganz,⁵ illustrates how little bone actually surrounds the natural tooth root. The concept that clinicians should strive to achieve 2.0 mm of bone buccal to the implant is difficult to achieve when the buccal cortical plate has been shown to be 1.0 mm or less with cross-sectional imaging. A CBCT study entitled “Classification of Sagittal Root Position in Relation to The Anterior Maxillary Osseous Housing” revealed the minimal bone surrounding natural teeth, and the relationship of the tooth root within the anterior maxillary alveolus as found in cross-sectional slices.⁶

The Root Membrane Concept was developed with the intent of maintaining hard and soft tissue by retaining a portion of the tooth root.⁷ The RMK provides a logical step-by-step protocol to carefully section and prepare the root approximately 3.0 mm below the gingival crestal tissue. Specially designed diamond burs allow for the root fragment to be prepared in a *c*- or *crescent moon*-shape when viewed occlusally. The central part of the root fragment should ideally measure from 1.5 to 2.0 mm in a buccal-lingual direction. The lingual or palatal placement of the implant requires precision drilling to avoid migration of the drill due to the slope of the cortical socket housing (Figure 4c). Therefore, after contouring the root fragment, a shaper diamond bur is utilized and followed by a tapered diamond (Figure 4d) to prevent accidental skipping of the drill, which can result in dislodgement of the root membrane. Once the osteotomy has been completed, the implant fixture can be delivered to the site within the TOB without touching the root membrane. If the gap distance is small, there is no need to fill the space, as evidenced by recent 5-year results² and soon-to-be-published 10-year results. Of great importance is that recent human histological examinations (submitted for

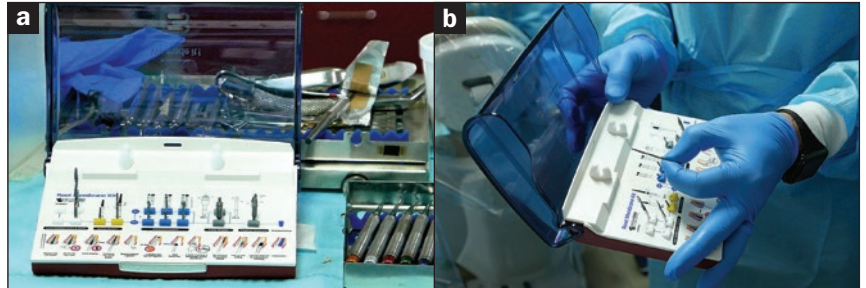


Figure 7. The Root Membrane Kit (integrated dental systems) contains a step-by-step protocol to remove the gutta-percha, section the tooth, and contour the root in anticipation of the implant.

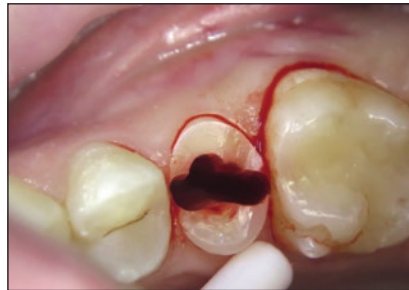

Figure 8. The tooth root was then sectioned horizontally and vertically as per the CBCT scan and treatment plan.

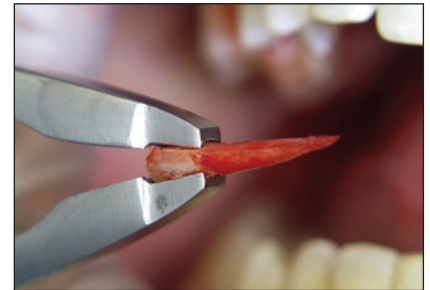


Figure 9. The separated palatal aspect of the root was carefully removed.

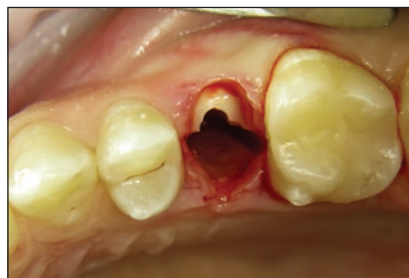

Figure 10. The coronal aspect of the root was recontoured to provide sufficient clearance for the implant.

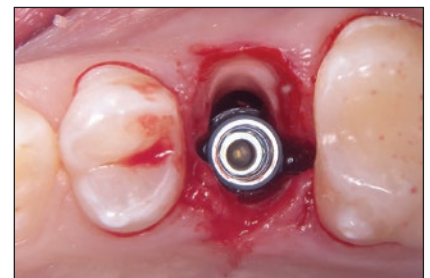


Figure 11. A 4.5-mm diameter by 13.0-mm length implant (AnyRidge [integrated dental systems]) was carefully placed, gaining apical stabilization at 45 Ncm of torque.

publication) reveal that it is possible for the root membrane to remain under functional load throughout time with new bone growth between the implant and the root surface, thus filling the gap. As demonstrated by Kan et al,⁶ the root position or trajectory, as evidenced in the cross-sectional or sagittal plane, may not be appropriate to retain the root. Case selection is critical for long-term success.

The previous use of CT and, currently, CBCT imaging modalities continues to define the state-of-the-art and the standard

The Root Membrane Concept: *In the Zone With the “Triangle of Bone”*

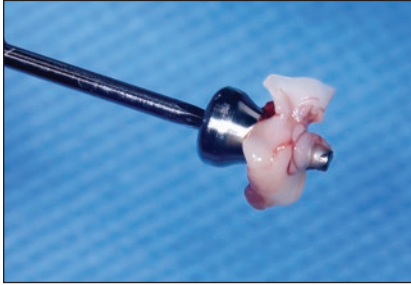


Figure 12. The implant stability allowed for a one-stage surgical approach utilizing platelet-rich fibrin wrapped around a titanium healing collar in a “poncho” technique.

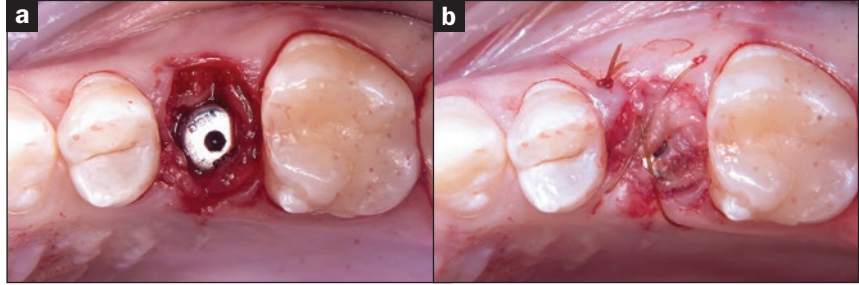


Figure 13. (a) The occlusal view of the implant site and (b) after suturing.

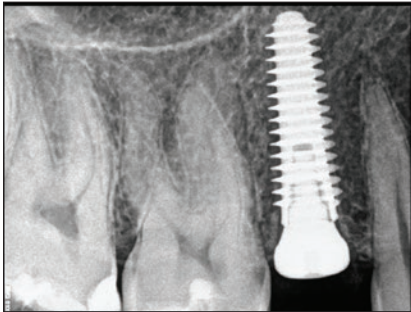


Figure 14. A periapical radiograph revealed excellent subcrestal positioning of the implant.

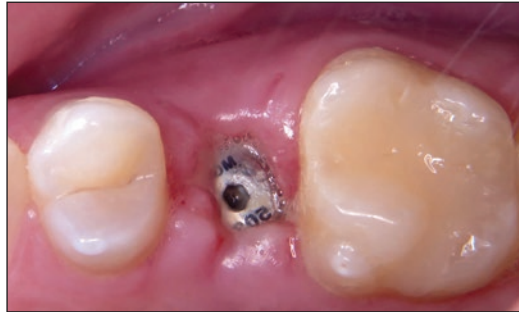

Figure 15. The 2-week follow-up appointment revealed the site's good soft-tissue healing.

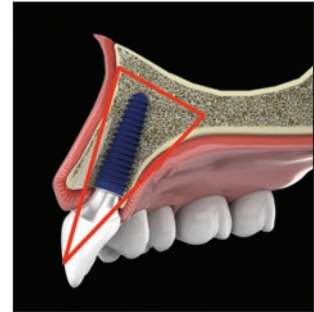


Figure 16. The TOB position should allow for maximum volume of bone surrounding the implant while avoiding contact with the root membrane.

for a true diagnostic understanding of the patient's individual anatomy.^{8,9} For more than 25 years, the TOB concept¹ has described a protocol for assessing potential implant receptor sites and/or the need for hard- and soft-tissue grafting. As innovative treatment protocols such as the Root Membrane Concept, Socket-Shield, and/or PET continue to evolve, clinicians can rely on the TOB to accurately assess the individual nature of each patient presentation to make educated decisions and to achieve predictable surgical and restorative outcomes.♦

References

1. Ganz SD. The triangle of bone—a formula for successful implant placement and restoration. *Implant Soc.* 1995;5:2-6.
2. Siompas KD, Mitsias ME, Kontsiotou-Siompas E, et al. Immediate implant placement in the esthetic zone utilizing the “root-membrane” technique: clinical results up to 5 years postloading. *Int J Oral Maxillofac Implants.* 2014;29:1397-1405.
3. Hürzeler MB, Zühr O, Schupbach P et al. The socket-shield technique: a proof-of-principle report. *J Clin Periodontol.* 2010;37:855-862.
4. Gluckman H, Du Toit J, Salama M. The pontic-shield: partial extraction therapy for ridge preservation and pontic site development. *Int J Periodontics Restorative Dent.* 2016;36:417-423.
5. Ganz SD. The reality of anatomy and the triangle of bone. *Inside Dentistry.* 2006;2:72-77.
6. Kan JY, Roe P, Rungcharassaeng K, et al. Classification of sagittal root position in relation to the anterior maxillary osseous housing for immediate implant placement: a cone beam computed tomography study. *Int J Oral Maxillofac Implants.* 2011;26:873-876.
7. Mitsias ME, Siompas KD, Kontsiotou-Siompas E, et al. A step-by-step description of PDL-mediated ridge preservation for immediate implant rehabilitation in the esthetic region. *Int J Periodontics Restorative Dent.* 2015;35:835-841.
8. Tyndall DA, Price JB, Tetradis S, et al. Position statement of the American Academy of Oral and Maxillofacial Radiology on selection criteria for the use of radiology in dental implantology with emphasis on cone beam computed tomography. *Oral Surg Oral Med Oral Pathol Oral Radiol.* 2012;113:817-826.
9. Ganz SD. Defining new paradigms for assessment of implant receptor sites. The use of CT/CBCT and interactive virtual treatment planning for congenitally missing lateral incisors. *Compend Contin Educ Dent.* 2008;29:256-267.

The Root Membrane Concept: *In the Zone With the “Triangle of Bone”*

POST EXAMINATION INFORMATION

To receive continuing education credit for participation in this educational activity you must complete the program post examination and receive a score of 70% or better.

Traditional Completion Option:

You may fax or mail your answers with payment to Dentistry Today (see Traditional Completion Information on following page). All information requested must be provided in order to process the program for credit. Be sure to complete your “Payment,” “Personal Certification Information,” “Answers,” and “Evaluation” forms. Your exam will be graded within 72 hours of receipt. Upon successful completion of the post-exam (70% or higher), a letter of completion will be mailed to the address provided.

Online Completion Option:

Use this page to review the questions and mark your answers. Return to **dentalcetoday.com** and sign in. If you have not previously purchased the program, select it from the “Online Courses” listing and complete the online purchase process. Once purchased, the program will be added to your **User History** page where a **Take Exam** link will be provided directly across from the program title. Select the **Take Exam** link, complete all the program questions and **Submit** your answers. An immediate grade report will be provided. Upon receiving a passing grade, complete the online evaluation form. Upon submitting the form, your **Letter of Completion** will be provided immediately for printing.

General Program Information:

Online users may log in to **dentalcetoday.com** any time in the future to access previously purchased programs and view or print letters of completion and results.

POST EXAMINATION QUESTIONS

- Difficulty continues in finding agreement as to where an implant should be placed within a potential receptor site.**
 - True
 - False
- If it is desired to surround the implant with the most volume of bone, the implant is positioned to bisect the Triangle of Bone (TOB) necessitating a screw-retained restorative protocol.**
 - True
 - False
- To counter the negative effects of removing the tooth root, techniques have been published that recommend leaving a portion of the root intact helping to preserve the periodontal ligament and associated fibers.**
 - True
 - False
- In the technique described in this article, to ensure that the root remnant is thin enough and in a proper shape to avoid the implant, the root needs to be modified.**
 - True
 - False
- The Root Membrane Kit (integrated dental systems) contains a step-by-step protocol to remove the gutta-percha, section the tooth, and contour the root in anticipation of the implant.**
 - True
 - False
- Based upon the protocol documented by Siompas et al during the past 10 years, the residual buccal “gap” was filled with bone.**
 - True
 - False
- The Root Membrane Concept was developed with the intent of maintaining hard and soft tissue by retaining a portion of the tooth root.**
 - True
 - False
- The TOB concept, only in use now for about 3 years, has described a protocol for assessing potential implant receptor sites and/or the need for hard- and soft-tissue grafting.**
 - True
 - False



The Root Membrane Concept: *In the Zone With the “Triangle of Bone”*

PROGRAM COMPLETION INFORMATION

If you wish to purchase and complete this activity traditionally (mail or fax) rather than online, you must provide the information requested below. Please be sure to select your answers carefully and complete the evaluation information. To receive credit you must answer at least 6 of the 8 questions correctly.

Complete online at: dentalcetoday.com

TRADITIONAL COMPLETION INFORMATION:

Mail or fax this completed form with payment to:

Dentistry Today
Department of Continuing Education
100 Passaic Avenue
Fairfield, NJ 07004
Fax: 973-882-3622

PAYMENT & CREDIT INFORMATION:

Examination Fee: \$40.00 Credit Hours: 2
 Note: There is a \$10 surcharge to process a check drawn on any bank other than a US bank. Should you have additional questions, please contact us at (973) 882-4700.

- I have enclosed a check or money order.
 - I am using a credit card.
- My credit card information is provided below.
- American Express Visa MC Discover

Please provide the following (please print clearly):

 Exact Name on Credit Card

 Credit Card #

 Expiration Date

 Signature

This CE activity was not developed in accordance with AGD PACE or ADA CERP standards. CEUs for this activity will not be accepted by the AGD for MAGD/FAGD credit.

PERSONAL CERTIFICATION INFORMATION:

 Last Name (PLEASE PRINT CLEARLY OR TYPE)

 First Name

 Profession / Credentials License Number

 Street Address

 Suite or Apartment Number

 City State Zip Code

 Daytime Telephone Number With Area Code

 Fax Number With Area Code

 E-mail Address

ANSWER FORM: VOLUME 36 NO. 10 PAGE 80

- Please check the correct box for each question below.
- | | |
|---|---|
| 1. <input type="checkbox"/> a. True <input type="checkbox"/> b. False | 5. <input type="checkbox"/> a. True <input type="checkbox"/> b. False |
| 2. <input type="checkbox"/> a. True <input type="checkbox"/> b. False | 6. <input type="checkbox"/> a. True <input type="checkbox"/> b. False |
| 3. <input type="checkbox"/> a. True <input type="checkbox"/> b. False | 7. <input type="checkbox"/> a. True <input type="checkbox"/> b. False |
| 4. <input type="checkbox"/> a. True <input type="checkbox"/> b. False | 8. <input type="checkbox"/> a. True <input type="checkbox"/> b. False |

PROGRAM EVALUATION FORM

Please complete the following activity evaluation questions.
 Rating Scale: Excellent = 5 and Poor = 0

Course objectives were achieved. _____

Content was useful and benefited your clinical practice. _____

Review questions were clear and relevant to the editorial. _____

Illustrations and photographs were clear and relevant. _____

Written presentation was informative and concise. _____

How much time did you spend reading the activity and completing the test? _____

What aspect of this course was most helpful and why? _____

What topics interest you for future *Dentistry Today* CE courses?
